

CHAPTER 19

Botulism as an Intestinal Toxemia

Stephen S. Arnon

Traditionally, botulism has been known as a foodborne disease and as such has always been of interest to gastroenterologists. Eighteen years ago the traditional view of botulism was revised and expanded following the recognition of a new form of the disease, i.e., infant botulism. Infant botulism is an infection of the intestinal tract in which ingested *Clostridium botulinum* spores germinate, multiply, and temporarily colonize the lumen of the large intestine and produce botulinum toxin in it. A minute fraction of the intraluminal toxin is then absorbed and carried by the bloodstream to peripheral cholinergic synapses, where it binds irreversibly. Clinically, the neuromuscular junction is the most important peripheral cholinergic synapse, and its poisoning by botulinum toxin results in hypotonia and flaccid paralysis. Botulinum neurotoxin is the most poisonous substance known. Its seven serologically distinguishable forms have arbitrarily been given the letters A–G. These seven toxin types serve as convenient clinical and epidemiological markers.

Recognition of infant botulism led to the discovery of two novel clostridial species that can make botulinum-like neurotoxins and colonize the human colon. Discovery of these additional neurotoxic clostridia necessitated a better descriptive term for the infectious form of botulism, now referred to as “the intestinal toxemias of infancy” or “intestinal toxemia botulism.” The distinction from diseases caused by other toxin-producing intestinal bacteria (e.g., *Shigella dysenteriae* type 1, *Escherichia coli*, *Vibrio cholerae*) is that the intestinal toxemia clostridia neither invade the mucosa (like *Shigella* or some *E. coli*) nor produce a mucosally active toxin (like *V. cholerae* or other *E. coli*). Under exceptional circumstances (e.g., changes in normal anatomy and gut flora), adults can become ill with “infant-type” botulism. Intestinal toxemia botulism in infants and adults is the subject of this chapter.

HISTORY

Reliable descriptions of foodborne botulism date to nineteenth century Germany, where Kerner described an illness known locally as “sausage poisoning.” In 1895 in the small Belgian town of Ellezelles, an outbreak occurred among 34 musicians who had eaten from a raw ham preserved in salt brine. Twenty-three persons became sick, 13 severely, and 3 died. This episode of botulism became famous because Emile van Ermengem (1851–1922), Professor of Microbiology at the University of Ghent, carried out a now classical investigation that established the essential aspects of botulism. van Ermengem discovered the obligatorily anaerobic, spore-forming bacterium known today as *Clostridium botulinum* and its phenomenally potent heat-labile toxin, which caused a wide variety of vertebrate animals to die from flaccid muscle paralysis. Much subsequent work in the United States on the ecology of the bacterium and the eradication of its spores from canned foods was carried out in the early decades of the twentieth century by Meyer, Dack, and colleagues (1).

The second form of human botulism to be recognized, wound botulism, was first reported in 1951 (1). Wound botulism is an infectious disease and is the pathophysiological equivalent of tetanus. Wound botulism remains the rarest form of human botulism, with somewhat over 100 cases reported worldwide. An occasional case of wound botulism has occurred as a complication of intestinal surgery (2). Wound botulism was the subject of a recent review (3) and will not be discussed further here.

Infant botulism, the third form of human botulism, was recognized as a distinct clinical and epidemiological entity in 1976 (4,5), more than 50 years after Orr had first demonstrated the possibility experimentally (6). Shortly after modern recognition of the first cases and the naming of the entity, the novel pathogenesis of infant botulism was demonstrated (7,8). Discovery in the late 1970s of a laboratory-proven case of infant botulism that occurred in 1931, yet was misdiagnosed at the time, helped confirm that infant botulism was not a “new” disease but only a

S. S. Arnon, MD: Infant Botulism Prevention Program, California Department of Health Services, Berkeley, California 94704.

newly recognized one (9). The first case of infant botulism to be caused by type F botulinum toxin was recognized in New Mexico in 1979 (10); later the causative bacterium of this case was found to be a unique strain of *Clostridium baratii* that produced a type F-like botulinum toxin (11,12). The first and thus far only two cases of infant botulism caused by type E toxin were recognized in Rome, Italy in 1986 (13), which resulted in discovery of a unique strain of *Clostridium butyricum* that produced a type E-like botulinum toxin (12,14).

Once the intestinal toxemias of infancy had been recognized, it became apparent that intestinal toxemia botulism could occur in older children and adults under exceptional, nonphysiological circumstances. The first case report that provided impeccable evidence of infant-type botulism in an adult appeared in 1986 (15). To date, recognized intestinal toxemia botulism has resulted from any of the three neurotoxic clostridial species of *C. botulinum*, *C. baratii*, and *C. butyricum*. However, other systemic illnesses presently considered idiopathic may possibly find their explanation in the toxins of the various clostridial species that are capable of colonizing the large intestine, if a search for them is made.

Most recently, botulinum toxin has become celebrated as the first microbial toxin to be harnessed into service as a medicine for the treatment of human disease (16-18). The toxin is used to treat a variety of ophthalmological and neurological conditions characterized by overactivity or spasm of a particular muscle or muscle group (19).

INFECTIOUS AGENTS

Clostridia by definition are the obligatorily anaerobic, gram-positive, spore-forming rods. Clinical botulism from an intestinal toxemia may be caused by any of three clostridial species that produces either botulinum neurotoxin itself or a closely related botulinum-like neurotoxin. These three species are *C. botulinum* and one unique strain each within the species *C. baratii* and *C. butyricum* (11-14).

In general, each strain of *C. botulinum* produces a single toxin type. However, strains that produce predominantly one toxin type together with a lesser amount of a second toxin type are known and have been given the designations Ab (20), Af (21), Ba (22), and Bf (23). By use of the polymerase chain reaction, it was recently shown that 43/79 (54%) of type A strains examined also carried the gene for type B toxin (24). However, only 1 of these 43 type A strains expressed biologically active type B toxin, thus defining it as an Ab strain. A further remarkable finding was the discovery of the type B toxin gene in two strains of *Clostridium subterminale*, neither of which by bioassay expressed the toxin gene (24). The identification of the gene(s) for botulinum and botulinum-like toxins in an increasing variety of non-*C. botulinum* species suggests that these toxin-encoding genes may await discovery in other clostridial species not yet examined.

The fourth clostridial species known to produce a neurotoxin, *C. tetani*, is apparently unable to colonize the human infant intestinal tract, as least as judged by the absence of reported clinical cases. However, the almost

universal immunization of women in the developed world with tetanus toxoid and the in utero transfer of maternal antibody to the fetus may prevent clinically evident cases of infant intestinal tetanus toxemia from occurring, while in the less developed world, tetanus in infancy is usually ascribed to "tetanus neonatorum." Perhaps tetanus neonatorum cases, especially those 2 months of age and older that lack an obvious wound source of toxin, should be evaluated for the possibility of intestinal colonization by *C. tetani*.

The bacterial species designated as *C. botulinum* is not a homogeneous collection of metabolically similar bacteria. Instead, the species was intentionally created as an aggregate of the strains that produce botulinum neurotoxin. This taxonomic decision preceded by several decades the discovery of the neurotoxic strains of *C. baratii*, *C. butyricum*, and *C. botulinum* type G. *Clostridium botulinum* is subdivided into four groups based on cultural and biochemical criteria. Group I consists of proteolytic strains that produce botulinum neurotoxin types A, B, and F; group II consists of nonproteolytic strains that produce neurotoxin types B, E, and F; group III consists of the strains that produce neurotoxin types C and D; and group IV consists of a single strain that produces neurotoxin type G (1). This latter group was recently proposed for inclusion in a new species, *C. argentinense* (25). In the next few years the nomenclature for all *C. botulinum* strains will probably be revised as ribosomal RNA and DNA hybridization techniques disclose the more correct taxonomic relationships between botulinum neurotoxin-producing strains and their nonneurotoxic clostridial counterparts (26, 26a, 26b).

Seven antigenic variations of botulinum neurotoxins exist and are distinguished from each other by the absence of cross-neutralization by monovalent antitoxins. These seven toxin types have been arbitrarily assigned the letters A-G (1). Because the neurotoxins produced by *C. butyricum* and *C. baratii* can be neutralized by either botulinum type E or type F antitoxin, respectively, these latter neurotoxins are referred to as "botulinum-like." The structural genes for the two botulinum-like toxins have been sequenced; the type E-like toxin has approximately 97% homology to classical botulinum type E toxin (27,28), while the type F-like toxin has approximately 70% homology to classical nonproteolytic type F botulinum toxin (29).

Botulinum toxin is the most poisonous poison known, and tetanus toxin is second only to botulinum toxin in potency (30). The extreme poisonousness of these two toxins derives from their specificity for synaptic neural cells and their enzymatic action that prevents synaptic transmission (see next section). The lethal (bloodstream) dose of botulinum toxin for a human has been estimated by extrapolation from primate and other animal studies to be less than, and perhaps substantially less than, 1 ng/kg (18,31); tetanus toxin is approximately one order of magnitude less potent (30,31).

PATHOGENESIS AND PATHOPHYSIOLOGY

As presently known, intestinal toxemia botulism results from ingestion of spores of any one of three neurotoxi-

genic clostridial species: *C. botulinum*, *C. butyricum*, and *C. baratii*. All three species produce either botulinum neurotoxin or botulinum-like neurotoxin in the lumen of the large intestine (32,33). The toxin is then absorbed from the colon and carried by the bloodstream to peripheral cholinergic synapses, the clinically most important of which is the neuromuscular junction. The toxin binds to unmyelinated terminal nerve endings and blocks their release of acetylcholine, thereby producing flaccid paralysis.

In its active form botulinum toxin consists of two peptide chains linked by at least one disulfide bond. The larger or "heavy" chain (~100,000 Da) contains the binding site by which the toxin attaches to the exterior surface of the nerve cell membrane. The different toxin serotypes apparently bind to different cell surface receptors (34). After the heavy chain attaches to the cell surface of the neuron, the "light" chain (~50,000 Da) and N terminal of the heavy chain are taken inside the cell by an endosome, the low internal pH of which apparently reduces the disulfide bond(s) and frees the light chain. The light chain then emerges into the cell cytoplasm and poisons acetylcholine release through its enzymatic action (35).

After centuries of curiosity and wonder, the basis of the extreme specificity and potency of the botulinum toxins was recently discovered (36). The light chain of the seven botulinum toxin serotypes and also of tetanus toxin was found to be zinc-containing endoproteases (37). Their substrates are various components of the "docking," or "togetherness," complex of proteins that enable the synaptic vesicle to fuse with the nerve cell terminal membrane and thereby release its acetylcholine into the synaptic cleft. These docking proteins have been given various names and acronyms, e.g., VAMP, SNAP-25, (38). Botulinum toxin type B and tetanus toxin were the first of the group to have their molecular mechanism understood (36). These two toxins as well as botulinum toxin types D, F, and G cleave the VAMP protein. Botulinum toxin types A and E cleave the SNAP-25 protein, and botulinum toxin type C cleaves the syntaxin protein (37,37a-c).

The central role of the normal intestinal microflora of adult animals in preventing *C. botulinum* spore germination and colonization of the large intestine has been elegantly shown in a mouse model system, in which the animals paradoxically remained asymptomatic (39-41). Administration of 10^6 type A spores failed to colonize the intestine of normal adult mice. However, after 2½ days treatment per os with a combination of erythromycin and kanamycin, half the mice could be colonized by just 2×10^4 spores, a 50-fold decrease in inoculum size. But when the antibiotic-treated mice were placed in cages with normal, untreated mice, they became resistant to intestinal colonization in 3 days (41). Because mice are coprophagic, the antibiotic-treated animals presumably had no difficulty in reacquiring a normal mouse intestinal flora from their cagemates. Additional work with germ-free animals emphasized the importance of normal flora as a protective barrier to colonization. Adult, germ-free mice could be colonized by just 10 *C. botulinum* type A spores, whereas after 3 days in a room that also housed conventional adult mice in different cages, the formerly germ-free animals

became resistant to colonization by 10^5 spores (40). Because this experimental design precluded coprophagy, the normal mouse intestinal flora must have been acquired by different means.

When infant mice rather than adult mice were used as the experimental animals, their intestines were found to be naturally susceptible to intestinal colonization by *C. botulinum* spores. Unlike the adult mice, pretreatment with antibiotics was not necessary to achieve colonization (39). However, like human infants, intestinal colonization of the normal flora infant mice occurred only within a restricted age interval (for mice, 7-13 days of age). Susceptibility of infant mice to intestinal colonization peaked between days 8 and 11 in a manner similar to the peaking of human infant susceptibility to intestinal *C. botulinum* colonization between 2 and 4 months of age (Fig. 1) (39,42). In addition, the infective dose of *C. botulinum* spores for infant mice was much smaller than that of their antibiotic-treated adult counterparts. For normal flora infant mice the 50% infective dose was only 700 spores. In one experiment, just 10 spores colonized an infant mouse (39). The minimum infective dose of *C. botulinum* spores for human infants is not known, but based on exposure to spore-containing honeys, it is estimated to be between 10 and 100 spores (43).

In the context of the pathophysiology of intestinal toxemia botulism, it should be emphasized that adults and older children regularly ingest small numbers of *C. botulinum* spores normally present in both cooked and fresh agricultural products (e.g., honey) without experiencing ill effects (44). The presumed explanation for this seeming paradox is that the fully developed and diversified intestinal microflora, present at a density of 10^{11} - 10^{12} anaerobes per gram of feces, prevents germination and outgrowth by the few ingested *C. botulinum* spores.

Parenthetically, intestinal colonization with *C. tetani* could be achieved experimentally when adult germ-free rats were fed vegetative cells, but not spores, of *C. tetani*, yet the animals remained asymptomatic (45). Conventional flora adult mice fed *C. tetani* spores became colonized only when the inoculum contained 10^6 or more spores. Even at this inoculum size, no tetanus toxin was found in the intestinal lumen 24 hr after ingestion of the inoculum (46). Also, adult chickens (47) and infant and germ-free adult rats (48) have been studied as model systems for infant botulism, as have adult horses and foals (49). The illness produced in the foals after feeding *C. botulinum* spores may in actuality have been intestinal wound (necrotic ulcer) botulism (49).

Recognition of the central role of the host intestinal microflora in determining susceptibility or resistance to colonization by *C. botulinum* directed attention to factors that might influence the composition of the normal microflora. Diet is probably the most important of these factors in the infant. In comparison with the adult-type flora, the infant flora is simpler, with fewer genera and species. The dominant members vary, depending in part on whether the infant is fed only breast milk, only formula milk, or a mixture of the two (50,51). Also, the composition of intestinal flora is changed if solid food such as

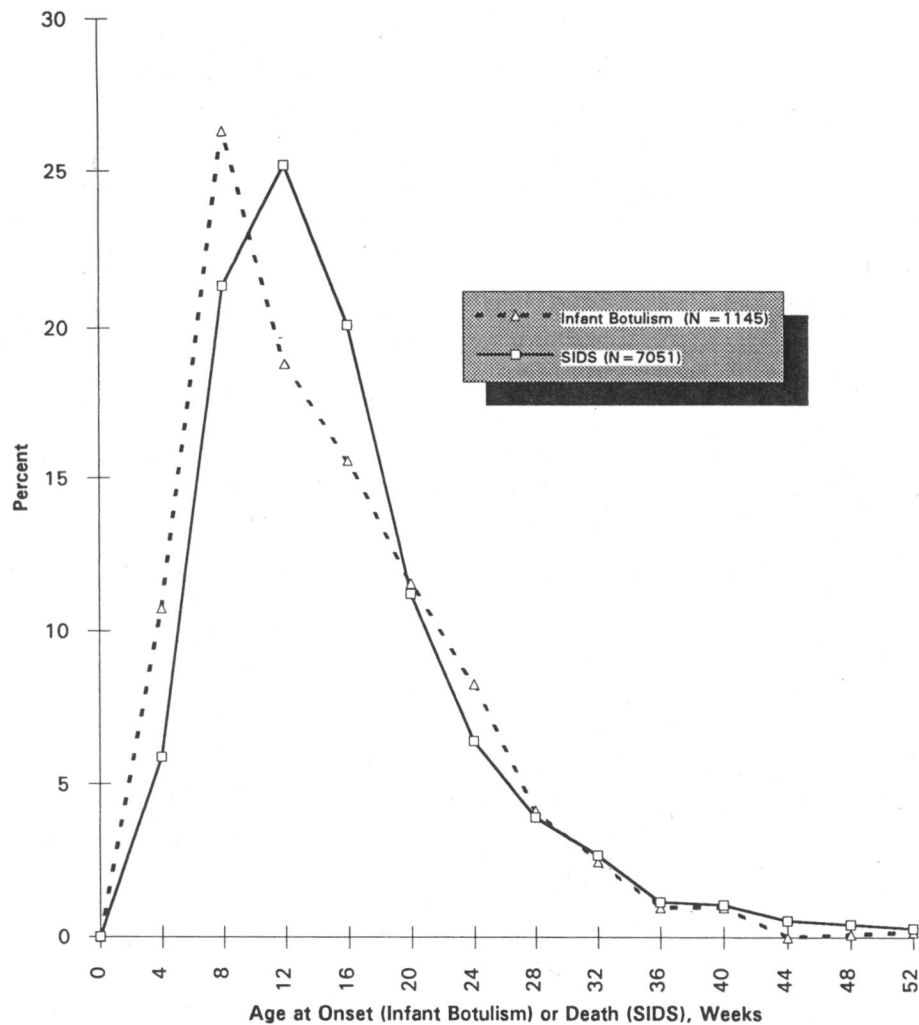


FIG. 1. Comparison of the age distribution of all hospitalized cases of infant botulism in the United States 1976–1992 ($N = 1145$) and all cases of sudden infant death syndrome (SIDS) in California ($N = 7051$). Age in days at onset (infant botulism) or at death (SIDS) converted to weeks.

cereals become part of the infant's diet (50,51). The normal human infant microflora contains several bacterial species, mainly *Bifidobacterium* and *Bacteroides*, that in vitro can inhibit the multiplication of *C. botulinum* (52).

Onset of infant botulism occurs at a significantly younger age in formula-fed infants (7.6 weeks) than in breast-fed infants (13.7 weeks) (53), perhaps reflecting the earlier availability in formula-fed infants of suitable ecological niches (50–53) and the formula-fed infant's lack of immune factors (e.g., SIgA, lactoferrin, lysozyme, etc.) contained in human milk (33,54,55). In addition, introduction of solid foods may "perturb" the intestinal microflora (50,51) and thereby aid in colonization by *C. botulinum* spores (33,42,56).

EPIDEMIOLOGY

The descriptive epidemiologies of intestinal toxemia botulism in infants and in adults are different. The adult

form will be discussed first, although generalizations are necessarily limited because less than a dozen cases of intestinal toxemia botulism in older children and adults are known (see end of section "Clinical Aspects" for specifics). Almost all adult intestinal toxemia botulism cases had either an underlying alteration of normal intestinal anatomy because of surgery or inflammatory bowel disease, or an alteration of the normal intestinal microflora from broad-spectrum antibiotic usage, or both. Adult intestinal toxemia botulism has affected both men and women in widely separated parts of the United States. No common source of ingested *C. botulinum* spores has been identified. Because the potentially at-risk population for adult intestinal toxemia botulism is so large, consisting of older persons who have had intestinal surgery, inflammatory bowel disease, and exposure to antibiotics, and because recognized cases are so few, either this illness occurs only rarely or it is often unrecognized.

The descriptive epidemiology of intestinal toxemia botulism in infants derives almost entirely from investigation

of hospitalized cases, which represents only a portion of the clinical spectrum of illness (33,57-59). Present epidemiological generalizations may need to be revised as the outpatient and sudden death portions of the clinical spectrum become more clearly defined (42,60-63).

Notably, the infant is the only family member ill. Ninety-five percent of cases occur in children less than 6 months old. The age-at-onset distribution of infant botulism is matched only by one other condition, the sudden infant death syndrome (SIDS, crib death) (Fig. 1) (42,64). The youngest case showed symptoms at 6 days of age (65,66), while the oldest was 363 days old (67). The M/F ratio of cases is essentially 1:1. Cases have occurred in all major racial and ethnic groups. Infant botulism has now been reported from all inhabited continents except Africa.

Infant botulism has become the most common form of human botulism recognized in the United States (33). In the years 1976-1992, a total of 1145 cases of infant botulism were reported in the United States, where approximately 75-100 cases are recognized annually. Another 63 cases have been reported from 17 other countries. About half of the U.S. cases have been reported from California, which has the largest number of births of any U.S. state. However, California does not have the highest incidence of infant botulism once adjustment is made for differences in annual births (Table 1). Notably, only two of the ten highest incidence states are located east of the Rocky Mountains. However, the figures for absolute numbers of cases and for incidence should be viewed with caution because they depend on correct physician recognition and reporting of this uncommon illness. Only five U.S. cases have been outpatients, and all five were recognized by physicians with prior experience with the more classical hospitalized patient and who therefore requested the stool testing needed to document the mild part of the clinical spectrum. In the United States cases of infant botulism have occurred in all calendar months. When viewed nationally, seasonal fluctuation appears limited, with a slight surge in the three fall months August-October (30.4% of cases), and a slight trough in the three winter months December-February (22.2% of cases).

The geographic distribution of U.S. cases is uneven. Approximately two thirds of cases have been reported by

the 13 states located in the Rocky Mountains and westward (including Hawaii and Alaska), while the remaining one third of cases was reported from the other 37 states (Table 1). In the 13 western states, *C. botulinum* type A was responsible for approximately two thirds of cases, whereas in the 37 easterly states, *C. botulinum* type B was responsible for approximately four fifths of cases. This asymmetrical distribution of case toxin types parallels the asymmetrical distribution of *C. botulinum* toxin types in American soils (68). Interesting geographic clusters of infant botulism have been recognized, such as in a small mountain town in Colorado (69) and in the "doughnut" distribution of cases around the core city of Philadelphia, Pennsylvania (56,57). All U.S. cases of infant botulism resulted from either type A or type B toxin except for one case with both toxin types (Hawaii), two cases with type Bf (both probably New Mexico), and one case caused by neurotoxicogenic *C. baratii* type F (New Mexico).

Identified risk factors for illness include a slow intestinal transit time (less than one stool per day) (58,70) and ingestion of honey (42,43,58,70a,71,72). Honey from a variety of geographic origins is a known reservoir of *C. botulinum* spores (7,73-80), and all major pediatric and public health agencies in the United States have recommended that infants not be fed honey for the first 12 months of life (references in 42). Breastfeeding appears to provide protection against the fulminant, sudden death presentation of infant botulism (53).

IMMUNITY

No child who has recovered from infant botulism has experienced a second episode of the illness. Whether this outcome results from the development of immunity or from maturation of the intestinal microflora, or simply from the rarity of the disease, is unknown. Although "relapses" of infant botulism have been reported, a close reading of those reports suggests that the patients were just discharged too soon, i.e., before they had recovered adequate strength to feed and breathe on their own (81,82). However, patients may regain sufficient strength to permit hospital discharge even while still excreting *C. botulinum* toxin and organisms in their feces (7,83,84); in these circumstances, it is presumed that they have developed neutralizing antibody (serum or secretory or both) against the toxin. Such antibody, if present, can be demonstrated only with the mouse neutralization test. However, one study of three serum specimens from two patients with infant botulism that used only an enzyme-linked immunosorbent assay (ELISA) technique and crude botulinum toxoid as the capture antigen detected an antibody rise to this mixture of antigens of *C. botulinum* (85).

PATHOLOGY

Because botulinum toxin is not a cytotoxin, the acute illness does not result in observable histological or bio-

TABLE 1. Cases and incidence of infant botulism, top ten incidence states, United States, 1977-1992

State	Cases	Incidence ^a
Delaware	16	10.0
Hawaii	29	9.7
Utah	53	8.5
California	538	7.1
Pennsylvania	121	4.7
Washington	40	3.6
Oregon	24	3.6
New Mexico	15	3.5
Idaho	9	3.2
Arizona	24	2.6

^a Per 100,000 live-births.

chemical pathology. With poisoning and loss of the trophic influence of acetylcholine, the synaptic cleft degenerates, and acetylcholinesterase activity spreads diffusely across the muscle cell membrane. Muscle atrophy also occurs. Recovery from botulinum toxin poisoning occurs through regeneration of the terminal unmyelinated nerve twigs. Once reformed, these twigs induce formation of new synaptic clefts, thereby restoring the neuromuscular junction. During recovery, new motor twigs emerge both terminally as well as preterminally from the distal nodes of Ranvier. With time the preterminal axonal sprouts atrophy, leaving the terminal neuromuscular junctions to initiate muscle contraction (86,87).

CLINICAL ASPECTS

Clinical Manifestations of Botulism

The classical triad of botulism consists of the acute to subacute onset of (a) a symmetrical, descending flaccid paralysis notably involving bulbar musculature, (b) a clear sensorium, and (c) the absence of fever. This triad may be useful in assessing adult cases, but it is less useful with infants because of their inability to describe symptoms. Infant botulism patients typically present with different complaints articulated by the parents.

Because toxemia is the pathophysiology common to all forms of botulism, and because blood flow to the head, face, throat, and neck musculature is relatively greater than blood flow to limb and trunk musculature, botulism always first manifests as weakness and paralysis of bulbar musculature. *It is not possible to have botulism without having at least some cranial nerve palsies.* However, careful and repetitive (i.e., sustained) examination may be required to identify bulbar palsies, particularly in mild cases. *Fatigability with any repetitive muscle activity is the clinical hallmark of botulism,* and this fact can be put to diagnostic use (Table 2). Botulism is a pure motor paralysis because only peripheral cholinergic synapses are affected; sensory nerves remain intact. Rarely, adult patients with botulism may complain of paresthesias; these paresthesias are thought to result from hyperventilation and anxiety as the patient perceives his or her muscles failing to work.

Like other infectious diseases, infant botulism displays a spectrum in its clinical severity (5,7,33,56,82,89). The onset ranges from the gradual to the abrupt. At one extreme are patients who returned to their physicians three or more times in a week as the signs of illness slowly became evident, while at the other extreme are patients who were nursing normally 6–8 hr before becoming so limp that acute meningitis was the diagnosis at presentation.

Because almost all patients recognized to date have been sufficiently paralyzed to need hospitalization, the present picture of infant botulism derives from the hospitalized patient. However, mildly weak and hypotonic cases managed as outpatients have been discerned by alert physicians familiar with the more "classical" manifestations. At the opposite end of the clinical spectrum are those few cases whose history and presentation are indistinguishable from typical cases of the SIDS (42,57,58,60–63). There appears to be geographic variation in the proportion of SIDS cases that may be attributable to intestinal toxemia botulism (42,57,58,60–63). A recent autopsy study concluded that, like *C. botulinum*, *C. perfringens* and its toxin(s) may also play a role in SIDS via the intestinal toxemia pathway (90,91). Other bacterial toxins have also been proposed as causes of SIDS (92–97).

Parents typically notice constipation (defined as 3 or more days without a bowel movement in an infant previously defecating at least every other day), lethargy, listlessness, and poor feeding as the initial symptoms of infant botulism. A nursing mother may experience breast engorgement because of the child's weakened strength and duration of sucking. These early symptoms may be followed within hours to days by an expressionless face; a weak, moaning, or high-pitched cry; drooling (the inability to swallow); loss of head control ("head lag"); generalized weakness; hypotonicity; and, not infrequently, frank respiratory arrest. Iatrogenic respiratory arrest has occurred when positioning patients for lumbar puncture, thus compromising their already marginal airway and respiratory ability.

Mild cases or those with gradual onset often have been brought back repeatedly to office, clinic, or emergency room settings and been given alternative diagnoses (Table

TABLE 2. Neurological signs helpful in the diagnosis of infant botulism

Test	Findings
1. Take patient to dark room. Shine a bright light into the eye; note quickness of pupillary constriction. Remove the light when the constriction maximal; let pupil dilate again. Then immediately repeat the light, continuing thus for 1–3 min.	The initially brisk pupillary constriction may become sluggish and unable to constrict maximally. (Fatigability with repetitive muscle contraction is the clinical hallmark of botulism.)
2. Shine a bright light onto the fovea, keeping it there for 1–3 min, even if the infant tries to deviate his eyes.	Latent ophthalmoplegia may be elicited and/or purposeful efforts to avoid the light may diminish.
3. Place a clean fifth finger in the infant's mouth, taking care not to obstruct the airway. Note the strength and duration of the reflex sucking.	The suck is weak and poorly sustained.

Adapted from ref. 88, with permission.

TABLE 3. Working differential diagnosis of infant botulism

Admission diagnosis	Subsequent working diagnosis
r/o Sepsis	Amino acid metabolic disorder
Dehydration	Brainstem encephalitis
Viral	Drug ingestion
syndrome	Guillain-Barré syndrome
Pneumonia	Heavy metal poisoning (Pb, Mg, As)
Idiopathic	Hirschsprung disease
hypotonia	Hypothyroidism
Failure to thrive	Medium-chain acetyl-CoA dehydrogenase (MCAD) deficiency
	Metabolic encephalopathy
	Myasthenia gravis
	Poliomyelitis
	Viral polyneuritis
	Werdnig-Hoffmann disease

3). Consideration of any of these diagnoses should also call to mind the possibility of infant botulism. A history of having been fed honey is not necessary for making the diagnosis; at present less than 5% of confirmed cases (in California) have been fed honey before onset. The suspicion of infant botulism necessitates a careful cranial nerve examination, in which drooling and poor feeding are understood to represent dysphagia, a weak cry to represent dysphonia, and ptosis to represent oculomotor palsy rather than "sleepiness" or "systemic toxicity" (Fig. 2).

Laboratory findings in botulism are generally normal because botulinum toxin is not cytotoxic to any tissue. The normality of virtually all laboratory screening tests may also help suggest the possibility of infant botulism. However, a minimally elevated blood urea nitrogen (BUN), or a mild ketonemia and ketonuria from diminished intake of fluid and food, may be present at emergency room or admission evaluation. Dehydration occasionally results in a slightly elevated cerebrospinal fluid (CSF) protein concentration. Both serum and CSF abnormalities promptly reverse with feeding and hydration. Electromyography (EMG) is the one bedside diagnostic study that may be helpful in infant botulism (see below).

Differential Diagnosis and Diagnosis

The principal differential diagnostic considerations are Guillain-Barré syndrome and myasthenia gravis. The effects of various toxic substances (e.g., organophosphate poisoning, tick bite) and metabolic conditions (e.g., medium-chain acetyl dehydrogenase deficiency, hypocalcemia, etc.) can be mistaken for botulism but are identifiable by proper laboratory investigation. In adults, the Miller-Fisher variant of Guillain-Barré syndrome (ophthalmoplegia, ataxia, areflexia) (98) may cause confusion, particularly since the CSF may initially be normal. However, in this disorder the onset of paralysis may not be symmetrical or it may be ascending, with bulbar musculature affected later rather than earlier in the course of illness. Paresthesias, asymmetry of paralysis, and an abnor-

mal CSF or nerve conduction velocity help distinguish classical Guillain-Barré syndrome from botulism. Myasthenia gravis spares the pupillary light reflex and has available for it three relatively sensitive and specific diagnostic tests: the presence of antiacetylcholine receptor antibody, the edrophonium (Tensilon) test, and EMG. With repetitive stimulation at high (50-Hz) frequency the EMG in myasthenia shows a decremental pattern, in contrast to the incremental pattern ("facilitation") seen in botulism.

The differential diagnosis in infant botulism is straightforward, even though the variety of conditions initially considered may be lengthy (Table 3). Today, 18 years after its recognition, the most common admission diagnosis for infant botulism still remains "rule out sepsis." As with many conditions, often the most difficult step in diagnosis is considering the possibility (Table 3). A careful history and neurological examination are essential to prompt diagnosis; very few diseases in the first 6 months of life present like infant botulism. Clues to diagnosis may be found on radiographs done for other reasons. The chest roentgenogram may show an infiltrate in apical lung segments consistent with aspiration, while an abdominal roentgenogram may show dilated, gas-filled loops of large bowel.

In infants, myasthenia gravis in the first 6 months of life is usually congenital; a history of maternal myasthenia establishes the diagnosis. Guillain-Barré syndrome properly documented by an elevated CSF protein is almost

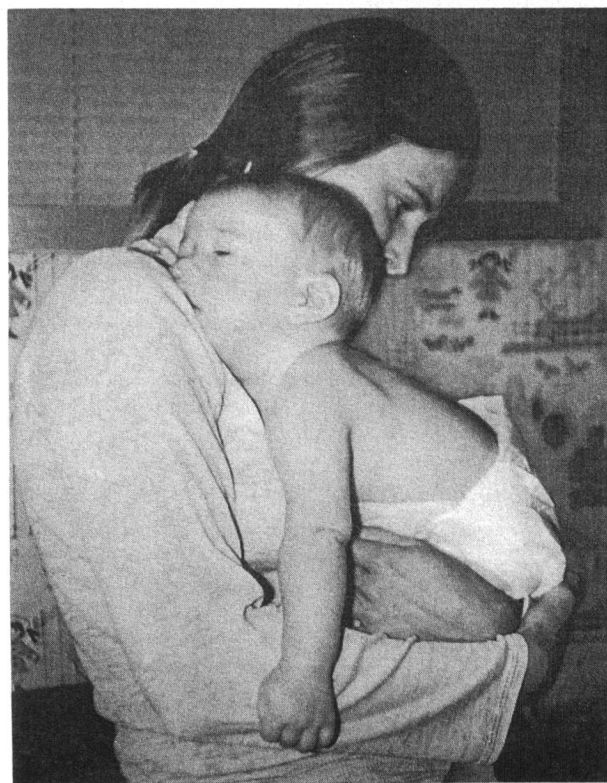

FIG. 2. Seven-week-old patient with mild infant botulism. Note ptosis, expressionless face, and lack of neck, arm, and truncal tone.

unknown in infancy. Metabolic disorders can be identified by appropriate testing of blood and urine. EMG is invasive, expensive, and painful, but can be helpful if the characteristic BSAP pattern is present (99,100). This pattern, seen in some but not all (101) patients with laboratory-confirmed infant botulism, has been given the acronym "BSAP" for "brief, small, abundant motor-unit potentials" (102). However, in a patient with a typical history and characteristic physical (especially neurological) examination, an EMG is usually not necessary if prompt testing of feces can be arranged through a state health department or Centers for Disease Control and Prevention (CDC) laboratory. The CDC's 24-hr notification telephone number is (404)639-2206 (Monday-Friday, 8:00 A.M.-5:00 P.M.) and (404)639-2888 (all other times). Other invasive and expensive diagnostic studies, such as MRI, CAT scan, EEG and muscle biopsy, yield normal or non-specific results and are incapable of diagnosing infant botulism.

Definitive diagnosis of intestinal toxemia botulism is established by identification of neurotoxicogenic *C. botulinum*, *C. baratii*, or *C. butyricum* organisms (with or without the concomitant presence of toxin) in the feces of a patient with an illness consisting of bulbar palsies, flaccid paralysis, and intact sensation and sensorium. Obtaining stool with which to carry out the necessary diagnostic studies may be difficult because of severe constipation; in this situation an enema with sterile, nonbacteriostatic water may be given. In suspect adult intestinal toxemia botulism cases, serum should also be examined for the possible presence of botulinum toxin. In the years ahead, molecular diagnostic (i.e., polymerase chain reaction) techniques may come to surpass the mouse bioassay in sensitivity and specificity (103-105).

Occasionally it is possible to identify small amounts (<5

mouse LD₅₀/mL) of botulinum toxin in the serum of infant patients if the specimen is collected early in the course of illness (13,83,106,107). In one report, almost one infant botulism patient in eight had toxin demonstrable in serum (106). Examination of feces by the mouse neutralization test remains the definitive diagnostic assay and should be done in all patients in whom the diagnosis is suspected. Clinically suspicious cases that lack an identified causative toxin type will not be included in official tallies of infant botulism (108). Physicians are also reminded that in most jurisdictions botulism or suspected botulism is an immediately reportable illness.

Clinical Course and Management

The course of infant botulism managed with meticulous supportive care has some generally predictable features. Following the acute to subacute onset of symptoms (hours to days), the progression of weakness eventually necessitates hospital admission. The nadir of hypotonicity and paralysis is generally reached about 1-2 weeks after admission. Patients may remain at this stage for as long as 2-3 weeks before showing improvement. Once improvement begins, it continues slowly over subsequent weeks (Fig. 3). Infant botulism does not have a relapsing course, and "regression" in a patient who has been improving should immediately launch a search for an occult complication (Table 4). The patient may be discharged once steady recovery is evident and gag reflex, sucking, and swallowing ability have returned, even though head lag and constipation may still be pronounced. Alternatively, the patient may be discharged somewhat earlier if the parents are able to feed the child by gavage at home.

Successful management of botulism is based on two

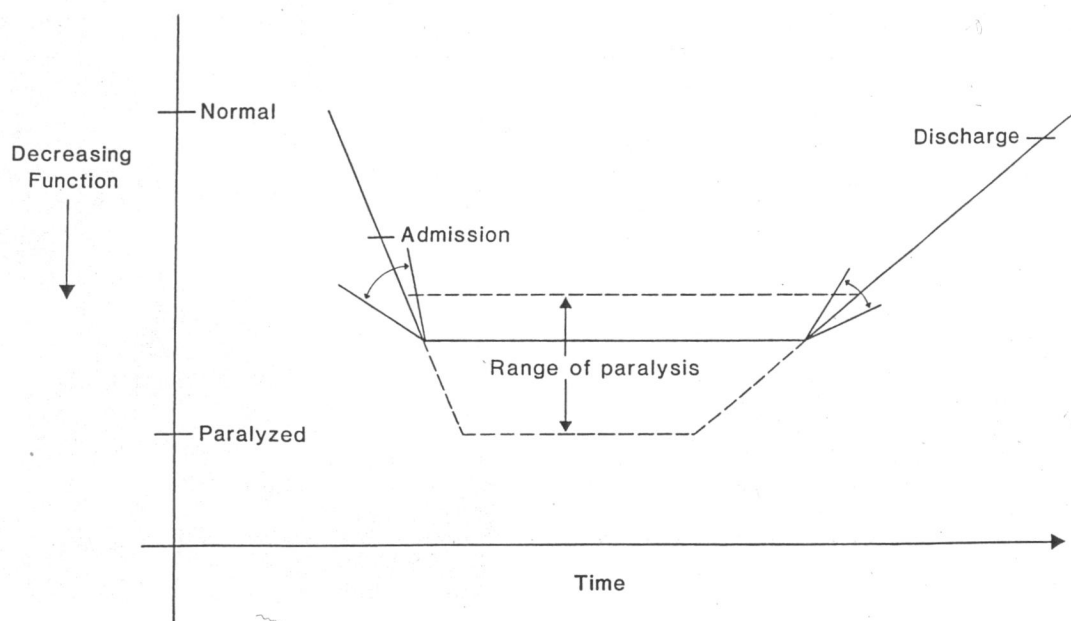


FIG. 3. Schematic course of infant botulism managed with meticulous supportive care. Time intervals intentionally omitted.

TABLE 4.—Complications of infant botulism

Adult respiratory distress syndrome
Aspiration
Fracture of the femur
Inappropriate antidiuretic hormone secretion
Misplaced or plugged endotracheal tube
Necrotizing enterocolitis
Otitis media
Pneumonia
Recurrent atelectasis
Seizures secondary to hyponatremia
Sepsis
Tension pneumothorax
Transfusion reaction
Urinary tract infection
Subglottic stenosis ^a
Tracheal granuloma ^a
Tracheitis ^a
Tracheomalacia ^a

^a A single hospital's experience (82).

principles: (a) that fatigability with repetitive muscle activity is the clinical hallmark of the disease and (b) that complications can best be avoided by anticipating them. The first principle is most applicable to feeding and breathing. A simple positioning maneuver improves respiratory mechanics and ventilation (Fig. 4). The patient is placed face up on a rigid-bottomed crib, the entire floor of which is tilted head up at 30°. A small cloth roll is placed under the neck to support the cervical vertebrae and to tip the head back so that oral secretions will drain into the posterior pharynx, where they are most easily swallowed. Some support (e.g., a sandbag) is often needed under the pelvis to prevent the patient from gradually sliding downhill. Also as a consequence of this position, the abdominal viscera pull the diaphragm down and thereby expand the thorax, thus improving the respiratory mechanics. Also, any regurgitated stomach contents must travel uphill for aspiration to result. It is undesirable to elevate the patient's head by flexing the crib bed and patient so that a

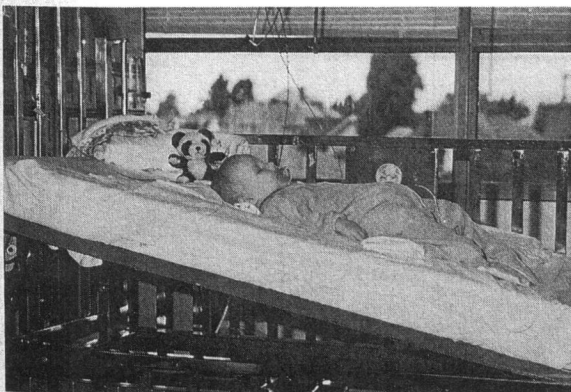


FIG. 4. Ideal positioning of an infant botulism patient. Note rigid mattress frame, 30° angle of entire body, small neck roll support. Brace under pelvis is to prevent downhill sliding.

bend occurs between thorax and abdomen. If this is done, the hypotonic thorax will settle onto the abdomen, making breathing difficult and tiring.

Intubation should be done prophylactically. Otherwise, fatigue of upper airway muscles will progress to pharyngeal musculature collapse, airway obstruction, and apnea. Transcutaneous carbon dioxide monitoring is useful in deciding when to intubate. A rising pCO₂ signals alveolar hypoventilation from fatigue and progressive paralysis of respiratory tract musculature. Approximately one third to one half of hospitalized patients will require intubation. Tracheostomy is almost never required because patients with global muscle paralysis and proper positioning can tolerate intubation for weeks or months without permanent sequelae (109,110).

Patients should be fed by nasogastric tube until it is certain that their strength of gag, suck, and swallow is sufficient to sustain them through an entire feeding by breast or bottle. Expressed breast milk is the nutritional fluid of choice, particularly because of the immune system components it contains (leukocytes, sIgA, lysozyme, lactoferrin, etc.). Tube feeding (nasogastric or nasojejunal) also assists in the resumption of peristalsis, a nonspecific but probably essential contributor to the eventual elimination of *C. botulinum* from the colonic microflora. Use of intravenous feeding (hyperalimentation) is discouraged both because of its potential for infection and because of the advantages of tube feeding.

Antibiotic administration is not part of the therapy of uncomplicated infant botulism. Botulinum toxin is primarily an intracellular molecule that is released by vegetative cell death and lysis. Consequently, clostridiocidal antibiotics may increase the amount of toxin available for absorption from a constipated large bowel and may actually worsen the patient's condition, a possibility apparently confirmed by recent clinical experience in California (California Department of Health Services, unpublished data). Antibiotic use in infant botulism should be reserved for the treatment of secondary infections. In these circumstances, a nonclostridiocidal antibiotic such as trimethoprim-sulfamethoxazole or nalidixic acid is preferred in order to minimize the release of additional toxin from *C. botulinum* vegetative cell death. Aminoglycoside antibiotics should be avoided because they may potentiate the blocking action of botulinum toxin at the neuromuscular junction (111).

Botulinum toxin does not cross the blood-brain barrier, but because the infant may appear comatose to the parents, they often need reassurance that brain damage has not occurred. Sensation remains intact, so patients are able to hear and feel normally. Accordingly, auditory, tactile, and visual stimuli should be provided, particularly in cases of prolonged hospital stay. Maintaining a strong central respiratory drive is essential in order to offset the peripheral blockade of neuromuscular transmission by botulinum toxin. For this reason, sedatives or other drugs that may cause central nervous system depression as a side effect, such as metoclopramide (Reglan), are contraindicated.

Constipation may be severe, so full hydration should be maintained. Stool softeners may be beneficial, but ca-

TABLE 5. Adults or children with intestinal

Patient age/sex (Ref.)	Location	Evidence for diagnosis
1. 37/F (15)	Maryland, USA	1. Type A botulinum toxin present in 2 serum specimens hospital days 11 and 13. Type A botulinum toxin present in 2 stool specimens hospital days 15 and 18. <i>C. botulinum</i> type A organisms present in 4 stool specimens hospital days 15–33. No evidence of wound or intraabdominal abscess by isotopic, computerized tomographic, endoscopic, or autopsy examination. <i>C. botulinum</i> type A organisms, but no toxin, found in the ingested creme of coconut. Husband who had also consumed the creme of coconut cocktails remained well.
2. 33/F (114, 116)	Oregon, USA	2. <i>C. botulinum</i> type A organisms present in feces hospital day 2.
3. 45/F (115)	Texas, USA	3. <i>C. botulinum</i> type B organisms present in feces at or after hospital admission.
4. ca. 70/M (116)	Kentucky, USA	4. Botulinum toxin type B present in serum on hospital day 30. Botulinum toxin type B present in feces hospital day 22. <i>C. botulinum</i> type B organisms present in feces hospital day 32.
5. 27/M (116)	Iceland	5. Onset of clinical botulism 40 days after eating home-made sausage. Type B botulinum toxin in serum 47 days after eating home-made sausage. <i>C. botulinum</i> type B organisms in feces 47 days after eating home-made sausage. No toxin in serum 19 days after eating home-made sausage. Type B botulinum toxin in enrichment culture of feces 19 days after eating home-made sausage, but organisms could not be isolated.
6. 54/M (117)	Georgia, USA	6. Botulinum toxin, probably type F, present in serum hospital day 4. <i>C. baratii</i> type F organisms present in stool specimens hospital days 4 and 14. <i>C. botulinum</i> type B organisms present in feces hospital day 4.
7. 3/F (118)	California, USA	7. <i>C. botulinum</i> type A toxin and organisms in two fecal specimens one month apart. Serum negative for toxin.
8. 67/M ^c	Oregon, USA	8. Type A botulinum toxin in serum at admission; <i>C. botulinum</i> type A organisms present in feces six months after onset.
9. 48/F ^d	Indiana, USA	9. <i>C. botulinum</i> type B in feces.
10. 51/F ^e	California, USA	10. <i>C. botulinum</i> type B in feces. Serum negative for toxin.

^a French investigators reported type B botulinum toxin detectable in serum in 35.7% (10/28) of patients 2 or more weeks after they had eaten foods containing *C. botulinum* type B toxin and organisms. Fecal excretion of toxin and organisms was not studied. Three persons had type B toxin detectable in serum 87 or more days after eating a spoiled ham, two of whom inexplicably were reported to be asymptomatic (119).

^b Swiss investigators reported a puzzling patient with Guillain-Barré syndrome in whom type F botulinum toxin was twice found in serum, once at days 10–28 and again at days 67–74 after onset, during which time the patient was continuously in the hospital. During these episodes, *C. botulinum* type F toxin and organisms were also present in feces. No food was suspected as a source of *C. botulinum* (120).

toxemia botulism (confirmed or possible)^{a,b}

Possible predisposing circumstances	Comment
1. Onset 5 weeks s/p antrectomy, vagotomy, and Billroth type I anastomosis for peptic ulcer disease. Received broad-spectrum cephalosporin preoperatively. Five days before onset, patient consumed cocktails containing creme of coconut.	1. First case of adult intestinal toxemia botulism with impeccable supporting evidence. Probable source of <i>C. botulinum</i> spores identified, prior antibiotic exposure, no blind loop. Hospitalized continuously and died 8 months after onset.
2. Onset 3 years s/p ileojejunal bypass for obesity, with resultant shortened bowel and small bowel blind loop. Autopsy not obtained.	2. Blind loop; no prior antibiotic exposure. No wounds and no history suggestive of foodborne botulism. Died 17 days after onset.
3. Onset 10 years s/p cholecystectomy and 7 years s/p "gastric bypass" surgery for obesity, with resultant small bowel blind loop. Diarrhea, then constipation 1 month before admission.	3. Blind loop; possible prior antibiotic exposure, if any, unknown.
4. None known.	4. Evidence only suggestive. Wife became ill at same time and died before diagnostic studies done. <i>C. botulinum</i> type B organisms but no toxin found in three containers of unopened home-canned blackberries sufficiently acidic (pH \leq 3.6) to prevent outgrowth of spores.
5. None known. To external appearances, intestinal tract apparently normal anatomically, physiologically, and microbiologically.	5. His 3 children developed type B foodborne botulism within 2 days after eating the home-made sausage. His wife developed type B botulism with toxin in her sum and type B organisms in her feces 12 days after eating the sausage. The sausage eaten by the husband may have contained only vegetative cells of <i>C. botulinum</i> , or a large number of spores, or both.
6. Onset 4 years s/p vagotomy, pyloroplasty, and cholecystectomy.	6. No prior antibiotics, no wounds, no history suggestive of foodborne botulism. Hospital stay of 31 days; chronic weakness and fatigue postdischarge.
7. Onset 7 weeks s/p radiation therapy, chemotherapy, and autologous bone marrow transplantation for neuroblastoma. Postoperative routine oral and occasional parenteral broad-spectrum antibiotic treatment. Ingestion of honey-coated dry cereal and vegetable-containing, microwave reheated frozen dinner prior to onset.	7. First case of nosocomially acquired intestinal toxemia botulism. Patient was treated with botulism immune globulin (IND-4283) under "compassionate use" provisions. Recovered from botulism, but died from recurrence of neuroblastoma.
8. Crohn's disease	8. Prior antibiotic exposure, if any, unknown.
9. Interval between colostomy for bowel cancer and onset not available.	9. Prior antibiotic and chemotherapy exposure, if any, unknown.
10. Onset 14 years s/p ileojejunal bypass for obesity. Began eating honey 2 weeks before onset, two aliquots of which were negative for <i>C. botulinum</i> spores.	10. Took an oral penicillin and an antacid for approximately one week before onset. First adult case with a history of honey exposure.

^c Griffin PM et al., Centers for Disease Control and Prevention (CDC), *personal communication*.

^d Hatheway CL et al., CDC, *personal communication*.

^e California Department of Health Services and CDC, *unpublished data*.

thartics are not recommended. The majority of patients require no special measures beyond occasional rectal stimulation or a glycerin suppository. Infrequently, a small inspissated fecal plug can occupy the rectal vault and must be manually removed before regular defecation can resume. Enemas intended to remove *C. botulinum* and toxin are useless because the bacterium colonizes the entire length of the large bowel (32).

Patients with infant botulism excrete both *C. botulinum* toxin and organisms in the feces for periods ranging from weeks to months. Consequently, scrupulous handwashing should be practiced after changing the diapers, which should be autoclaved. Persons with open lesions on their hands should not handle soiled diapers. The potentially lengthy excretion of toxin and organisms (occasionally longer than 3 months) precludes close contact between recuperating patients and healthy infants during this time (e.g., sharing a crib or toys). The eventual exclusion of *C. botulinum* from the resident fecal flora, which occurs in all patients, further confirms that this bacterium is a pathogen when present in a symptomatic person.

Bladder atony may be present and increases the risk of urinary tract infection. Gentle manual pressure on the bladder (the Credé method) can be used to achieve emptying. Doing so is best done as a two-person maneuver, with one person sitting the infant up and supporting the head and airway, and the other using two hands (one behind the sacrum) to squeeze the bladder. Indwelling catheters or frequent intermittent catheterizations are not recommended because of their ability to initiate a urinary tract infection.

The second principle of management, the avoidance of complications, is aided by noting past experience (Table 4). Because daily change in an infant botulism patient may be almost imperceptible, there can be a deceptive dullness to its management that may lull the unwary physician into an erroneous complacency. All complications listed in Table 4 were nosocomially acquired, some iatrogenically. A few of these complications represent the irreducible minimum that accrues to critically ill, paralyzed infants who must reside in intensive care units for weeks or months while being entirely dependent on extracorporeal life support systems.

Efforts to improve the treatment of infant botulism continue. A human-derived botulinum antitoxin, known formally as botulism immune globulin, is undergoing investigational new drug evaluation for efficacy in California (112). The results of this randomized, placebo-controlled, double-blinded, phase II study, whose outcome measures are progression of paralysis, incidence of complications, and length and cost of hospital stay, are expected to become available by 1997.

Recovery and Prognosis

Recovery in botulism occurs through regeneration of terminal and subterminal unmyelinated nerve twigs. These sprouts then induce formation of new motor endplates, thereby restoring neuromuscular transmission. Clinically and in experimental animals, this process takes

several weeks for completion (86,87). Once neuromuscular transmission is restored, movement resumes. No lasting neuromuscular effects of intestinal toxemia botulism have been observed in infants, but some adults with foodborne botulism have reported chronicity of weakness and fatigue (113). The reasons for this difference may include variation in the amount of toxin absorbed from the gut or variation in the regenerative capacity of adult and infantile motor nerve endings.

Infant botulism caused by type A toxin is potentially, but not invariably, more severe and expensive than that caused by type B toxin. In California, the mean hospital stay for 226 patients with type A illness was 5.6 weeks (median 4.6) at a mean (median) cost of \$91,000 (\$50,900) per case, whereas the mean hospital stay for 155 patients with type B illness was 3.7 weeks (median 3.4) at a mean (median) cost of \$68,300 (\$57,700) per case ($p < 10^{-4}$). Hospital costs for all patients from 1984 to 1993 averaged \$2400 per day. One quarter of patient had hospital stays that cost \$100,000 or more; the most expensive case was hospitalized for 10 months at a cost exceeding \$890,000. (All dollar amounts are adjusted to 1993 constant dollars.)

Most patients recover fully from infant botulism. When death occurs, it is not a direct action of the botulinum toxin itself. Instead, death results from complications and the resulting need for intensive care. The case fatality ratio of infants hospitalized with intestinal toxemia botulism in the United States now stands at less than 1%. This remarkably low figure is a tribute to the high quality of intensive care available to these often critically ill, severely paralyzed infants. The experience in other parts of the world has not been so fortunate.

Clinical Circumstances of Adult and Toddler Intestinal Toxemia Botulism

Because botulism in older persons has traditionally been known as a foodborne intoxication, the special circumstances in which intestinal toxemia botulism has occurred in adults deserve description. Somewhat less than a dozen cases of intestinal toxemia botulism in adults and older children have been reported (15,114–118), a situation that is consistent with the presumed rarity of the condition and its current underrecognition.

The clinical circumstances, possible predisposing factors, and supporting diagnostic findings of the known cases of adult and childhood intestinal toxemia botulism are summarized in Table 5. The potentially predisposing features common to most—but not all—cases appear to consist of (a) an altered intestinal tract anatomy, either from surgery or inflammatory bowel disease, (b) an altered intestinal tract physiology (vagotomy, achlorhydria, parenteral nutrition, decreased motility), and (c) an altered intestinal microflora following broad-spectrum antibiotic treatment. The more puzzling circumstance is the Icelandic man who apparently had a normal intestinal tract and acquired intestinal toxemia botulism approximately 6 weeks after simply ingesting *C. botulinum* organisms, either as a large number of vegetative cells or spores, or both.

PREVENTION

Infant botulism and the intestinal toxemias of infancy result from ingestion of the spores of various neurotoxic clostridial species. Circumstantial evidence suggests that most infant patients inhale spores carried by microscopic (i.e., invisible) dust that then sticks to saliva and is swallowed. Such cases are presently unpreventable. The easy availability of dustborne botulinum spores in many parts of the world yet the rarity of clinical cases of infant botulism attests to the importance of host factors such as diet and microflora in determining whether or not a given child who swallows spores will develop clinical illness. Breastfeeding appears to slow the onset of illness and to diminish the risk of respiratory arrest in those infants in whom the disease develops (53).

The one identified, avoidable source of botulinum spores for infants is honey (33,43). All major pediatric and public health agencies in the United States concur that honey should not be fed to any child less than 12 months of age [references in (42)]. Cases of infant botulism attributable to spore-containing honey have also been reported from Canada, Italy, and Japan (70a-72). Corn syrups were once considered a possible source of botulinum spores but on the basis of more recent evidence are no longer thought to be (121). Additional prevention measures may emerge from a better understanding of the composition and determinants of the infant intestinal microflora, the pathophysiological key to this unique infectious disease.

REFERENCES

- Smith LDS, Sugiyama H. *Botulism: the Organism, its Toxins, the Disease*. 2nd Ed. Springfield, IL: Charles C. Thomas; 1988.
- Isacsohn M, Cohen A, Steiner A, Rosenberg P, Rudensky B. Botulism intoxication after surgery in the gut. *Isr J Med Sci* 1985;21:150-153.
- Weber JT, Goodpasture HC, Alexander H, Werner SB, Hatheway CL, Tauxe RV. Wound botulism in a patient with a tooth abscess: case report and review. *Clin Infect Dis* 1993;16:635-639.
- Pickett J, Berg B, Chaplin E, Brunstetter-Shafer M. Syndrome of botulism in infancy: clinical and electrophysiologic study. *N Engl J Med* 1976;295:770-772.
- Midura TF, Arnon SS. Infant botulism: identification of *Clostridium botulinum* and its toxins in faeces. *Lancet* 1976;2:934-936.
- Orr PF. The pathogenicity of *Bacillus botulinus*. *J Infect Dis* 1922;30:118-127.
- Arnon SS, Midura TF, Clay SA, Wood RM, Chin J. Infant botulism: epidemiological, clinical, and laboratory aspects. *JAMA* 1977;237:1946-1951.
- Wilcke BW Jr, Midura TF, Arnon SS. Quantitative evidence of intestinal colonization by *Clostridium botulinum* in four cases of infant botulism. *J Infect Dis* 1980;141:419-423.
- Arnon SS, Werner SB, Faber HK, Farr WH. Infant botulism in 1931: discovery of a misclassified case. *Am J Dis Child* 1979;133:580-582.
- Hoffman RE, Pincomb BJ, Skeels MR, Burkhart MJ. Type F infant botulism. *Am J Dis Child* 1982;136:270-271.
- Hall JD, McCroskey LM, Pincomb BJ, Hatheway CL. Isolation of an organism resembling *Clostridium barati* which produces type F botulinum toxin from an infant with botulism. *J Clin Microbiol* 1985;21:654-655.
- Suen JC, Hatheway CL, Steigerwalt AG, Brenner DJ. Genetic confirmation of identities of neurotoxicogenic *Clostridium barati* and *Clostridium butyricum* implicated as agents of infant botulism. *J Clin Microbiol* 1988;26:2191-2192.
- Aureli P, Fenicia L, Pasolini B, Gianfranceschi M, McCroskey LM, Hatheway CL. Two cases of type E infant botulism in Italy caused by neurotoxicogenic *Clostridium butyricum*. *J Infect Dis* 1986;54:207-211.
- McCroskey LM, Hatheway CL, Fenicia L, Pasolini B, Aureli P. Characterization of an organism that produced type E botulinum toxin but which resembles *Clostridium butyricum* from the feces of an infant with type E botulism. *J Clin Microbiol* 1986;23:201-202.
- Chia JK, Clark JB, Ryan CA, Pollack M. Botulism in an adult associated with food-borne intestinal infection with *Clostridium botulinum*. *N Engl J Med* 1986;315:239-240.
- Scott AB. Botulinum toxin injection into extraocular muscles as an alternative to strabismus surgery. *Ophthalmology* 1980;87:1044-1049.
- Jankovic J, Brin MF. Therapeutic uses of botulinum toxin. *N Engl J Med* 1991;324:1186-1194.
- Schantz EJ, Johnson EA. Properties and use of botulinum toxin and other microbial neurotoxins in medicine. *Microbiol Rev* 1992;56:80-99.
- Jankovic J, Hallet M (eds.). *Therapy with botulinum toxin*. New York: Marcel Dekker; 1994.
- Poumeyrol M, Billon J, DeLille F, Hass C, Marmonier A, Sebald M. Intoxication botulique mortelle due a une souche de *Clostridium botulinum* de type AB. *Méd Mala Infect* 1983;13:750-754.
- Giménez DF, Ciccarelli AS. Studies on strain 84 of *Clostridium botulinum*. *Zbl Bakt I, Abt Orig A* 1970;84:215-212-220.
- Giménez DF. *Clostridium botulinum* subtype Ba. *Zbl Bakt Hyg A* 1984;257:68-72.
- Hatheway CL, McCroskey LM. Unusual neurotoxicogenic clostridia recovered from human fecal specimens in the investigation of botulism. In: Hattori T, Ishida Y, Maruyama Y, Morita RY, Uchida A, eds. *Proceedings of the 5th International Symposium on Microbial Ecology: Recent Advances in Microbial Ecology*. Tokyo: Japan Scientific Societies Press; 1990:477-481.
- Franciosa G, Ferreira JL, Hatheway CL. Detection of types A, B, and E botulinum neurotoxin genes in *Clostridium botulinum* and other *Clostridium* species by the polymerase chain reaction: evidence of unexpressed type B toxin genes in type A toxigenic organisms. *J Clin Microbiol* 1994;32:1911-1917.
- Suen JC, Hatheway CL, Steigerwalt AG, Brenner DJ. *Clostridium argentinense* sp. nov.: a genetically homogeneous group composed of all strains of *Clostridium botulinum* toxin type G and some nontoxigenic strains previously identified as *Clostridium subterminale* or *Clostridium hastiforme*. *Int J System Bacteriol* 1988;38:375-381.
- East AK, Thompson DE, Collins MD. Analysis of operons encoding 23S rRNA of *Clostridium botulinum* type A. *J Bacteriol* 1992;174:8158-8162.
- Hutson RA, Thompson DE, Collins MD. Genetic interrelationships of saccharolytic *Clostridium botulinum* types B, E, and F and related clostridia as revealed by small-subunit rRNA gene sequences. *FEMS Microbiol Lett* 1993;108:103-110.
- Hutson RA, Thompson DE, Lawson PA, Schocken-Itturino RP, Bottger EC, Collins MD. Genetic interrelationships of proteolytic *Clostridium botulinum* types A, B, and F and other members of the *Clostridium botulinum* complex as revealed by small-subunit rRNA gene sequences. *Antonie van Leeuwenhoek* 1993;64:273-283.
- Poulet S, Hauser D, Quanz M, Niemann H, Popoff MR. Sequence of the botulinum neurotoxin E derived from *Clostridium botulinum* type E (strain Beluga) and *Clostridium butyricum* (strains ATCC 43181 and ATCC 43755). *Biochem Biophys Res Commun* 1992;183:107-113.
- Fujii N, Kimura K, Yashiki T, et al. Cloning and whole nucleotide sequence of the gene for the light chain component of botulinum type E toxin from *Clostridium butyricum* strain BL6340 and *Clostridium botulinum* type E strain Mashike. *Microbiol Immunol* 1992;36:213-220.

29. Thompson DE, Hutson RA, East AK, Allaway D, Collins MD, Richardson PT. Nucleotide sequence of the gene coding for *Clostridium baratii* type F neurotoxin: comparison with other clostridial neurotoxins. *FEMS Microbiol Lett* 1993;108:175-182.
30. Gill DM. Bacterial toxins: a table of lethal amounts. *Microbiol Rev* 1982;46:86-94.
31. Morton HE. The toxicity of *Clostridium botulinum* type A toxin for various species of animals, including man. Philadelphia: University of Pennsylvania, Institute for Cooperative Research, 1961.
32. Mills DC, Arnon SS. The large intestine as the site of *Clostridium botulinum* colonization in human infant botulism. *J Infect Dis* 1987;156:997-998.
33. Arnon SS. Infant botulism: anticipating the second decade. *J Infect Dis* 1986;154:201-206.
34. Black JD, Dolly JO. Interaction of ¹²⁵I-labeled botulinum neurotoxins with nerve terminals. I. Ultrastructural autoradiographic localization and quantitation of distinct membrane acceptors for types A and B on motor nerves. *J Cell Biol* 1986;103:521-534.
35. Simpson LL. Current concepts on the mechanism of action of clostridial neurotoxins. In: DasGupta BR, ed. *Botulinum and tetanus neurotoxins: neurotransmission and biomedical aspects*. New York: Plenum Press; 1993:5-15.
36. Schaivo G, Benfenati F, Poulain B, et al. Tetanus and botulinum-B neurotoxins block neurotransmitter release by proteolytic cleavage of synaptobrevin. *Nature* 1992;359:832-834.
37. Huttner WB. Snappy exocytosis. *Nature* 1993;365:104-105.
- 37a. Blasi J, Chapman ER, Link E, et al. Botulinum neurotoxin A selectively cleaves the synaptic protein SNAP-25. *Nature* 1993;365:160-163.
- 37b. Blasi J, Chapman ER, Yamasaki S, Binz T, Niemann H, Jahn R. Botulinum neurotoxin C1 blocks neurotransmitter release by means of cleaving HPC-1/syntaxin. *EMBO J* 1993;12:4821-4828.
- 37c. Schiavo G, Rossetto O, Catsicas S, et al. Identification of the nerve terminal targets of botulinum neurotoxin serotypes A, D, and E. *J Biol Chem* 1993;268:23784-23787.
38. Barinaga M. Secrets of secretion revealed. *Science* 1993;260:487-489.
39. Sugiyama H, Mills DC. Intraintestinal toxin in infant mice challenged intragastrically with *Clostridium botulinum* spores. *Infect Immun* 1978;21:59-63.
40. Moberg LJ, Sugiyama H. Microbial ecologic basis of infant botulism as studied with germfree mice. *Infect Immun* 1979;25:653-657.
41. Burr DH, Sugiyama H. Susceptibility to enteric botulinum colonization of antibiotic-treated adult mice. *Infect Immun* 1982;36:103-106.
42. Arnon SS, Damus K, Chin J. Infant botulism: epidemiology and relation to sudden infant death syndrome. *Epidemiol Rev* 1981;3:45-66.
43. Arnon SS, Midura TF, Damus K, Thompson B, Wood RM, Chin J. Honey and other environmental risk factors for infant botulism. *J Pediatr* 1979;94:331-336.
44. Easton EJ, Meyer KF. Occurrence of *Bacillus botulinus* in human and animal excreta. *J Infect Dis* 1924;35:207-212.
45. Wells CL, Balish E. *Clostridium tetani* growth and toxin production in the intestines of germfree rats. *Infect Immun* 1983;41:826-828.
46. Ebisawa I, Kigawa M, Takayanagi M. Colonization of the intestinal tract of mice with *Clostridium tetani*. *Jpn J Exp Med* 1987;57:315-320.
47. Miyazaki S, Sakaguchi G. Experimental botulism in chickens: the cecum as the site of production and absorption of botulinum toxin. *Jpn J Med Sci Biol* 1978;31:1-15.
48. Moberg LJ, Sugiyama H. The rat as an animal model for infant botulism. *Infect Immun* 1980;29:819-821.
49. Swerczek TW. Experimentally induced toxicoinfectious botulism in horses and foals. *Am J Vet Res* 1980;41:348-350.
50. Stark PL, Lee A. The microbial ecology of the large bowel of breast-fed and formula-fed infants during the first year of life. *J Med Microbiol* 1982;15:189-203.
51. Stark PL, Lee A. Clostridia isolated from the feces of infants during the first year of life. *J Pediatr* 1982;100:362-365.
52. Sullivan NM, Mills DC, Riemann HP, Arnon SS. Inhibition of growth of *Clostridium botulinum* by intestinal microflora isolated from healthy infants. *Microbiol Ecol Health Dis* 1988;1:179-192.
53. Arnon SS, Damus K, Thompson B, Midura TF, Chin J. Protective role of human milk against sudden death from infant botulism. *J Pediatr* 1982;100:568-573.
54. Goldman AS, Goldblum RM. Immunologic system in human milk: characteristics and effects. In: Leberthal E, ed. *Textbook of gastroenterology and nutrition in infancy*. 2nd Ed. New York: Raven Press; 1989:135-142.
55. Arnon SS. Breast feeding and toxigenic intestinal infections: missing links in crib death? *Rev Infect Dis* 1984;6:S193-S201.
56. Long SS, Gajewski JL, Brown LW, Gilligan PH. Clinical, laboratory, and environmental features of infant botulism in southeastern Pennsylvania. *Pediatrics* 1985;75:935-941.
57. Long SS. Epidemiologic study of infant botulism in Pennsylvania: report of the infant botulism study group. *J Pediatr* 1985;75:928-934.
58. Spika JS, Shaffer N, Hargrett-Bean N, Collin S, MacDonald KL, Blake PA. Risk factors for infant botulism in the United States. *Am J Dis Child* 1989;143:828-832.
59. Morris JG Jr, Snyder JD, Wilson R, Feldman RA. Infant botulism in the United States: an epidemiologic study of cases occurring outside of California. *Am J Public Health* 1983;73:1385-1388.
60. Arnon SS, Midura TF, Damus K, Wood RM, Chin J. Intestinal infection and toxin production by *Clostridium botulinum* as one cause of sudden infant death syndrome. *Lancet* 1978;1:1273-1277.
61. Peterson DR, Eklund MW, Chinn NM. The sudden infant death syndrome and infant botulism. *Rev Infect Dis* 1979;1:630-634.
62. Sonnabend OAR, Sonnabend WFF, Krech U, Molz G, Sigrist T. Continuous microbiological and pathological study of 70 sudden and unexpected deaths: toxigenic intestinal *Clostridium botulinum* infection in 9 cases of sudden infant death syndrome. *Lancet* 1985;1:237-240.
63. Byard RW, Moore L, Bourne AJ, Lawrence AJ, Goldwater PN. *Clostridium botulinum* and sudden infant death syndrome: a 10 year prospective study. *J Paediatr Child Health* 1992;28:156-157.
64. Beckwith JB. The sudden infant death syndrome. *Curr Probl Pediatr* 1973;3:3-36.
65. Thilo EH, Townsend SF, Deacon J. Infant botulism at 1 week of age: report of two cases. *Pediatrics* 1993;92:151-153.
66. Hurst DL, Marsh WW. Early severe infantile botulism. *J Pediatr* 1993;122:909-911.
67. Hubert P, Roy C, Caille B. Un cas de botulisme chez un nourrisson de 11 mois. *Arch Fr Pediatr* 1987;44:129-130.
68. Smith LDS. The occurrence of *Clostridium botulinum* and *Clostridium tetani* in the soil of the United States. *Health Lab Sci* 1978;15:74-80.
69. Istre GR, Compton R, Novotny T, Young JE, Hatheway CL, Hopkins RS. Infant botulism: three cases in a small town. *Am J Dis Child* 1986;140:1013-1014.
70. Schwarz PJ, Arnon JM, Arnon SS. Epidemiologic aspects of infant botulism in California, 1976-91. In: DasGupta BR, ed. *Botulinum and tetanus neurotoxins: neurotransmission and biomedical aspects*. New York: Plenum Press; 1993:503-504.
- 70a. Hauschild AHW, Hilsheimer R, Weiss KF, Burke RB. *Clostridium botulinum* in honey, syrups, and dry infant cereals. *J Food Protect* 1988;51:892-894.
71. Tabita K, Sakaguchi S, Kozaki S, Sakaguchi G. Distinction between *Clostridium botulinum* type A strains associated with food-borne botulism and those with infant botulism in Japan and in the intraintestinal toxin production in infant mice and some other properties. *FEMS Microbiol Lett* 1991;79:251-256.
72. Fenicia L, Ferrini AM, Aureli P, Pocco M. A case of infant botulism associated with honey feeding in Italy. *Eur J Epidemiol* 1993;9:671-673.
73. Sugiyama H, Mills DC, Kuo L-JC. Number of *Clostridium botulinum* spores in honey. *J Food Prot* 1978;41:848-850.

74. Midura TF, Snowden S, Wood RM, Arnon SS. Isolation of *Clostridium botulinum* from honey. *J Clin Microbiol* 1979;9:282-283.
75. Huhtanen CN, Knox D, Shimanuki H. Incidence and origin of *Clostridium botulinum* spores in honey. *J Food Prot* 1981;44:812-815.
76. Hauschild AHW, Hilsheimer R, Weiss KF, Burke RB. *Clostridium botulinum* in honey, syrups and dry infant cereals. *J Food Prot* 1988;51:892-894.
77. Nakano H, Okabe T, Hashimoto H, Sakaguchi G. Incidence of *Clostridium botulinum* in honey of various origins. *Jpn J Med Sci Biol* 1990;43:183-195.
78. Nakano H, Sakaguchi G. An unusually heavy contamination of honey products by *Clostridium botulinum* type F and *Bacillus alvei*. *FEMS Microbiol Lett* 1991;79:171-178.
79. Nakano H, Yoshikuni Y, Hashimoto H, Sakaguchi G. Detection of *Clostridium botulinum* in natural sweetening. *Int J Food Microbiol* 1992;16:117-121.
80. Berry PR, Gilbert RJ, Oliver RWA, Gibson AAM. Some preliminary studies on the low incidence of infant botulism in the United Kingdom (letter). *J Clin Pathol* 1987;40:121.
81. Glauser TA, Maguire HC, Sladky JT. Relapse of infant botulism. *Ann Neurol* 1990;28:187-189.
82. Schreiner MS, Field E, Ruddy R. Infant botulism: a review of 12 years' experience at the Children's Hospital of Philadelphia. *Pediatrics* 1991;87:159-165.
83. Paton JC, Lawrence AJ, Steven IM. Quantities of *Clostridium botulinum* organisms and toxin in feces and presence of *Clostridium botulinum* toxin in the serum of an infant with botulism. *J Clin Microbiol* 1983;17:13-15.
84. Paton JC, Lawrence AJ, Manson JI. Quantitation of *Clostridium botulinum* organisms and toxin in the feces of an infant with botulism. *J Clin Microbiol* 1982;15:1-4.
85. Rubin LG, Dezfulin M, Yolken RH. Serum antibody response to *Clostridium botulinum* toxin in infant botulism. *J Clin Microbiol* 1982;16:770-771.
86. Duchon LW. Motor nerve growth induced by botulinum toxin as a regenerative phenomenon. *Proc R Soc Med* 1972;65:196-197.
87. Angaut-Petit D, Molgo J, Comella JX, Faille L, Tabti N. Terminal sprouting in mouse neuromuscular junctions poisoned with botulinum type A toxin: morphological and electrophysiological features. *Neuroscience* 1990;37:799-808.
88. Arnon SS. Infant botulism. *Annu Rev Med* 1980;31:541-560.
89. Wilson R, Morris JG Jr, Snyder JD, Feldman RA. Clinical characteristics of infant botulism in the United States: a study of the non-California cases. *Pediatr Infect Dis* 1982;1:148-150.
90. Lindsay JA, Mach AS, Wilkinson MA, et al. *Clostridium perfringens* type A cytotoxic-enterotoxin(s) as triggers for death in the sudden infant death syndrome: development of a toxicoinfection hypothesis. *Curr Microbiol* 1993;27:51-59.
91. Mach AS, Lindsay JA. Activation of *Clostridium perfringens* cytotoxic enterotoxin(s) in vivo and in vitro: role in triggers for sudden infant death. *Curr Microbiol* 1994;28:261-267.
92. Telford DR, Morris JA, Hughes P, et al. The nasopharyngeal bacterial flora in the sudden infant death syndrome. *J Infect* 1989;18:125-130.
93. Bettelheim KA, Goldwater PN, Dwyer BW, Bourne AJ, Smith DL. Toxigenic *Escherichia coli* associated with sudden infant death syndrome. *Scand J Infect Dis* 1990;22:467-476.
94. McKendrick N, Drucker DB, Morris JA, et al. Bacterial toxins: a possible cause of cot death. *J Clin Pathol* 1992;45:49-53.
95. Malam JE, Carrick GF, Telford DR, Morris JA. Staphylococcal toxins and sudden infant death syndrome. *J Clin Pathol* 1992;45:716-721.
96. Drucker DB, Aluyi HS, Morris JA, Telford DR, Gibbs A. Lethal synergistic action of toxins of bacteria isolated from sudden infant death syndrome. *J Clin Pathol* 1992;45:799-801.
97. Murrell WG, Stewart BJ, O'Neill C, Siarakas S, Kariks S. Enterotoxigenic bacteria in the sudden infant death syndrome. *J Med Microbiol* 1993;39:114-127.
98. Berlit P, Rakicky J. The Miller Fisher syndrome: review of the literature. *J Clin Neuro-Ophthalmol* 1992;12:57-63.
99. Johnson RO, Clay SA, Arnon SS. Diagnosis and management of infant botulism. *Am J Dis Child* 1979;133:586-593.
100. Cornblath DR, Sladky JT, Sumner AJ. Clinical electrophysiology of infantile botulism. *Muscle and Nerve* 1983;6:448-452.
101. Graf WD, Hays RM, Astley SJ, Mendelman PM. Electrodagnosis reliability in the diagnosis of infant botulism. *J Pediatr* 1992;120:747-749.
102. Engel WK. Brief, small, abundant motor-unit action potentials: a further critique of electromyographic interpretation. *Neurology* 1975;25:173-176.
103. Szabo EA, Pemberton JM, Desmarchelier PM. Specific detection of *Clostridium botulinum* type B by using the polymerase chain reaction. *Appl Environ Microbiol* 1992;58:418-420.
104. Szabo EA, Pemberton JM, Desmarchelier PM. Detection of the genes encoding botulinum neurotoxin types A to E by the polymerase chain reaction. *Appl Environ Microbiol* 1993;59:3011-3020.
105. Fach P, Hauser D, Guillou JP, Popoff MR. Polymerase chain reaction for the rapid identification of *Clostridium botulinum* type A strains and detection in food samples. *J Appl Bacteriol* 1993;75:234-239.
106. Hatheway CL, McCroskey LM. Examination of feces and serum for diagnosis of infant botulism in 336 patients. *J Clin Microbiol* 1987;25:2334-2338.
107. Takahashi M, Noda H, Takeshita S, et al. Attempts to quantify *Clostridium botulinum* type A toxin and antitoxin in serum of two cases of infant botulism in Japan. *Jpn J Med Sci Biol* 1990;43:233-237.
108. Centers for Disease Control. Case definitions for public health surveillance. *MMWR* 1990;39 (No. RR-13):6-7.
109. Arnon SS. Infant botulism. In: Feigen RD, Cherry JD, eds. *Textbook of pediatric infectious disease*. 3rd Ed. Philadelphia: WB Saunders; 1992:1095-1102.
110. Wohl DL, Tucker JA. Infant botulism: considerations for airway management. *Laryngoscope* 1992;102:1251-1254.
111. Santos JI, Swensen P, Glasgow LA. Potentiation of *Clostridium botulinum* toxin by aminoglycoside antibiotics: clinical and laboratory observations. *Pediatrics* 1981;68:50-54.
112. Arnon SS. Clinical trial of human botulism immune globulin. In: DasGupta BR, ed. *Botulinum and tetanus neurotoxins: neurotransmission and biomedical aspects*. New York: Plenum Press; 1993:477-483.
113. Mann JM, Martin S, Hoffman R, Marrazzo S. Patient recovery from type A botulism: morbidity assessment following a large outbreak. *Am J Public Health* 1981;71:266-269.
114. English WJ, Williams LP Jr, Bryant RE, Gillies MD. Case 48-1980: botulism (letter). *N Engl J Med* 1981;304:789-790.
115. Freedman M, Armstrong RM, Killian JM, Boland D. Botulism in a patient with jejunioleal bypass. *Ann Neurol* 1986;20:641-643.
116. McCroskey LM, Hatheway CL. Laboratory findings in four cases of adult botulism suggest colonization of the intestinal tract. *J Clin Microbiol* 1988;26:1052-1054.
117. McCroskey LM, Hatheway CL, Woodruff BA, Greenberg JA, Jurgenson P. Type F botulism due to neurotoxicogenic *Clostridium botulinum* from an unknown source in an adult. *J Clin Microbiol* 1991;29:2618-2620.
118. Shen W-PV, Felsing N, Lang D, Goodman G, Cairo MS. Development of infant botulism in a 3-year-old female with neuroblastoma following autologous bone marrow transplantation: potential use of human botulism immune globulin. *Bone Marrow Transpl* 1994;13:345-347.
119. Sebald M, Saimot G. Toxémie botulique; intérêt de sa mise en évidence dans le diagnostic du botulisme humain de type B. *Ann Microbiol* 1973;124A:61-69.
120. Sonnabend WF, Sonnabend OA, Gründler P, Katz E. Intestinal toxicoinfection by *Clostridium botulinum* type F in an adult: case associated with Guillain-Barré syndrome. *Lancet* 1989;1:357-361.
121. Lilly T Jr., Rhodehamel EJ, Kautter DA, Solomon HM. *Clostridium botulinum* spores in corn syrup and other syrups. *J Food Protect* 1991;54:585-587.